

Research Article

Protective Effects of Miswak (*Salvadora persica*) against Experimentally Induced Gastric Ulcers in Rats

Mohamed A. Lebda ¹, Ali H. El-Far ², Ahmed E. Noreldin ³, Yaser H. A. Elewa,^{4,5}
Soad K. Al Jaouni,⁶ and Shaker A. Mousa ⁷

¹Biochemistry Department, Faculty of Veterinary Medicine, Alexandria University, Alexandria 22758, Egypt

²Biochemistry Department, Faculty of Veterinary Medicine, Damanhour University, Damanhour 22511, Egypt

³Histology and Cytology Department, Faculty of Veterinary Medicine, Damanhour University, Damanhour 22511, Egypt

⁴Histology and Cytology Department, Faculty of Veterinary Medicine, Zagazig University, Zagazig, Egypt

⁵Laboratory of Anatomy, Department of Biomedical Sciences, Graduate School of Veterinary, Hokkaido University, Sapporo, Japan

⁶Department of Pediatric Hematology/Oncology, King Abdulaziz University Hospital and Scientific Chair of Yousef Abdul Latif

Jameel of Prophetic Medicine Application, Faculty of Medicine, King Abdulaziz University, Jeddah 21589, Saudi Arabia

⁷Pharmaceutical Research Institute, Albany College of Pharmacy and Health Sciences, Rensselaer, NY 12144, USA

Correspondence should be addressed to Mohamed A. Lebda; lebdam1979@alexu.edu.eg
and Ali H. El-Far; ali.elfar@damanhour.edu.eg

Received 10 March 2018; Revised 26 April 2018; Accepted 24 May 2018; Published 9 July 2018

Academic Editor: Rohit Saluja

Copyright © 2018 Mohamed A. Lebda et al. This is an open access article distributed under the Creative Commons Attribution License, which permits unrestricted use, distribution, and reproduction in any medium, provided the original work is properly cited.

Gastric ulcers are among the most broadly perceived illnesses affecting individuals. Alcohol consumption is the main cause of gastric ulceration. This study assessed the protective effects of *Salvadora persica* (SP) extract against ethanol-induced gastric ulcer and elucidated the conceivable underlying mechanisms involved. For this purpose, 40 rats were allotted into 4 equal groups (control, ethanol- (EtOH-) treated, and SP-treated “SP200 and SP400” groups). The control and EtOH-treated groups were given phosphate buffer saline (PBS), and both the SP200 and SP400 groups were given SP extract dissolved in PBS at doses of 200 and 400 mg/kg b.w., respectively. All treatments were given orally for 7 constitutive days. On the 8th day, all rats were fasted for 24 h followed by oral gavage of PBS in the control group and chilled absolute ethanol solution (5 ml/kg b.w.) in the EtOH- and SP-treated groups to induce gastric lesions. One hour later, the rats were sacrificed and the stomachs were harvested. Gross and microscopic examinations of the EtOH-treated group showed severe gastric hemorrhagic necrosis, submucosal edema, destruction of epithelial cells, and reduced glycoprotein content at the mucus surface. These pathological lesions were defeated by SP extract treatment. Administration of SP extract modulated the oxidative stress and augmented the antioxidant defenses. The elevated ethanol-expressed tumor necrosis factor- α (TNF- α) and interleukin-1 β (IL-1 β) genes, as well as bcl-2-like protein 4 (Bax) and inducible nitric oxide synthase (iNOS), were diminished in the SP-treated group. Curiously, SP extract upregulated endothelial nitric oxide synthase (eNOS) and transforming growth factor- β 1 (TGF- β 1) gene expression comparable to that of the EtOH-treated rats. Aggregately, SP exerted antiulcer activities in ethanol-induced gastric ulcer rat models via modulation of oxidant/antioxidant status, mitigation of proinflammatory cytokines, and apoptosis, as well as remodeling of both NOS isoforms.

1. Introduction

Gastric ulceration mainly occurs as a result of disharmony between 5 inverse factors at the gastric mucosa [1]. Inducing factors include alcohol, nonsteroidal anti-inflammatory

drugs, smoking, stress, and *Helicobacter pylori* [2]. This is in contrast to the gastroprotective factors that are attributed to adequate secretion of mucus and prostaglandins, maintenance of anti-inflammatory and antioxidative agents, and normal mucosal blood flow [3].

Ethanol is one of the forceful factors that prompt gastric ulcer and is used as a model for assessment of the gastro-defensive effects of various drugs and natural products [4]. The oxidative stress that leads to the production of reactive oxygen species (ROS) along with the decline in antioxidative enzymes at the gastric mucosa induced by ethanol ingestion is implicated in the pathogenesis of ethanol-induced gastric ulceration [5]. Alcohol consumption induces gastric mucosal damage and apoptosis through tumor necrosis factor- α (TNF- α) signaling and ROS formation [6]. TNF- α , an initiating proinflammatory cytokine, has a critical role in the pathogenesis of gastric ulcer via inflammation and injury inducement [7]. Alcohol-induced gastric damage has been mediated through hypersecretion of gastric acid [8], proinflammatory cytokines and ROS generation [9], apoptosis induction, and depletion of nitric oxide (NO) and prostaglandin E2 [10]. NO, a vasodilator that is synthesized from the amino acid arginine by two NO synthases, has a dual function at the gastric mucosal level. One of them is the endothelial nitric oxide synthase (eNOS) that produces NO to assist gastric ulcer healing mainly through stimulation of blood vessels' formation, increasing blood flow, and anti-inflammatory action [11], while NO generated from inducible nitric oxide synthase (iNOS) functions in gastric ulcer induction via the formation of ROS and toxic effects on cells [12].

Alleviation of gastric aggressive mediators and progression of gastric preservative factors are considered as therapeutic tools for the healing of gastric ulcer [13]. The mechanism of the healing process encompasses the restoration of the gastro-defensive factors' balance, generation of gastric mucosal cells and blood vessels, matrix reconstruction, antioxidation, and anti-inflammation [14].

Natural products have attracted scientific attention as prophylactic alternatives for gastric ulcer [15]. *Salvadora persica* L. (SP), also known as miswak, a Salvadoraceae family member, has been used mainly as natural toothbrushes [16]. SP-lyophilized decoction has a protective action on gastric ulcer induced by acetylsalicylic acid in rats [17]. Soliman et al. [18] reported that SP root extract attenuated oxidative stress, restored antioxidant enzymes, and reduced glutathione (GSH) level in rats exposed to lead acetate. Also, Nomani et al. [19] showed that the anti-inflammatory activity of SP extract is mediated via the down-regulation of TNF- α mRNA expression in inflammatory bowel disease-induced rats. Further, the most potent inflammatory factors IL-1 β , TNF- α , and TGF- β 1 were decreased in rat serum subjected to carrageenan-induced paw edema pretreated with SP extract [20].

In view of previously published data concerning the mechanistic factors of gastric ulcer healing, the current study was designed to evaluate the effects of SP aqueous extract on proinflammatory cytokines, nitric oxide synthases, apoptotic pathways, and oxidative/antioxidative pathways involved in ethanol-induced gastric ulcer in rats.

2. Materials and Methods

2.1. Ethics Statement. The experiments were done in compliance with the rules set by the Ethics Committee at the Faculty

TABLE 1: Ingredients of basal diet.

Ingredients	g/kg diet
Corn flour	529.5
Casein	200
Sucrose	100
Soybean oil	70
Cellulose	50
Mineral mix	35
Vitamin mix	10
L-Cysteine	3
Choline	2.5

of Veterinary Medicine, Alexandria University, Egypt. All efforts were made to minimize the suffering of rats during experimentation and sampling.

2.2. Chemicals and Reagents. Absolute ethanol (EtOH) solution was purchased from Sigma-Aldrich Co. (St. Louis, MO, USA). Polyclonal rabbit anti-mouse iNOS antibody (1:100; Cat: ab15323), monoclonal rabbit anti-human Bax antibody (1:300; Cat: ab32503), polyclonal rabbit anti-mouse IL-1 β antibody (1:250; Cat: ab9722), and polyclonal rabbit anti-human CD3 antibody (1:100; Cat: ab5690) were purchased from Abcam Co., Cambridge, UK.

Kits for malondialdehyde (MDA), GSH, total superoxide dismutase (T.SOD), catalase (CAT), glutathione peroxidase (GPx), and glutathione S-transferase (GST) were obtained from Biodiagnostic Co. (Dokki, Giza, Egypt). Total RNA extraction and SYBR Green Master Mix kits were purchased from Qiagen Co., Germany. cDNA kit was obtained from Promega Co., Madison, WI, USA.

2.3. Plant Extraction. SP roots were purchased from the local market in Alexandria, Egypt, and authenticated at the Botany Department, Agriculture Faculty, Alexandria University. One kg of SP roots was cut into small pieces, air dried, and ground into fine powder and then extracted in distilled water for 48 h at 25°C. After centrifugation at 1435 \times g for 15 min, the resulting supernatants were filtered through Whatman number 1 filter paper and the filtrates were concentrated using a rotary evaporator at 40°C [21]. The obtained fine extract powder was subdivided into small portions in brown bottles and freshly prepared before supplementation to rats.

2.4. Gas Chromatography-Mass Spectrometry (GC-MS) Analysis of SP Phytochemicals in Extract. SP extract was dissolved in N,O-Bis(trimethylsilyl)trifluoroacetamide and injected into a Trace GC Ultra-ISQ mass spectrometer with a direct capillary column TG-5MS (30 m \times 0.25 mm \times 0.25 μ m). The GC was equipped with splitless mode/30 s with helium as a carrier gas. The temperature of the GC oven was maintained at 45°C for 30 s. The oven temperature was gradually raised to 235°C at a rate of 8°C/min and maintained at 235°C for 7.07 min. The MS ion source temperature was 150°C and mass spectra were obtained at 70 eV [22].

TABLE 2: Primer sequences.

Gene symbol	Gene description	GenBank accession number	Sequence	Annealing temperature (°C)
Actb	β -Actin	NM_031144.3	F: TGTTGTCCCTGTATGCCTCT R: TAATGTCACGCACGATTTCC	60
eNOS	Endothelial nitric oxide synthase	NC_005103.4	F: TCTTCAAGGACCTACCTCAGGC R: GCTAAGGCAAAGCTGCTAGGTC	60
TGF- β 1	Transforming growth factor- β 1	NM_021578.2	F: CCAACTACTGCTTCAGCTCCACA R: TGTACTGTGTGCCAGGCTCCAAA	58
TNF- α	Tumor necrosis factor- α	NM_012675.3	F: GACCCTCACACTCAGATCATCTTCT R: TTGTCTTTGAGATCCATGCCATT	60
IL-1 β	Interleukin-1 β	NM_031512.2	F: CACCTCTCAAGCAGAGCACAG R: GGGTTCATGGTGAAGTCAAC	60

Separated compounds were identified by comparing their mass spectra to the Wiley Registry 8e.

2.5. Animal Study Design and Induction of Gastric Ulcer. Forty male adult rats weighing between 240 and 250 g were purchased from the Animal Breeding Unit, Medical Research Institute, Alexandria University. Animals were housed in clean metal cages under optimum conditions proportionate to the Institutional Guideline for Care and Use of Laboratory Animals: temperature: $21 \pm 2^\circ\text{C}$, humidity: $56 \pm 5\%$, 12 h light/dark cycle, and free access to water and to diet as listed in Table 1.

Rats were allocated into the control group ($n = 20$), SP200 ($n = 10$) group that received SP extract 200 mg/kg b.w., and SP400 ($n = 10$) group that received SP extract 400 mg/kg b.w. [23, 24]. SP extract was dissolved in phosphate buffer saline (PBS) and given orally to the SP200 and SP400 groups for 7 days while the control group received only PBS. On the 8th day, all rats were fasted for 24 h followed by administration of ethanol by gastric tube to induce gastric lesions to 10 rats of the control group and all rats in the SP200 and SP400 groups; rats were gavaged with chilled absolute ethanol solution 5 ml/kg b.w. according to the method described by Park et al. [25]. The remaining 10 rats of the control group were gavaged with PBS and kept as negative control. One hour following the induction of gastric lesions, the rats were sacrificed under anesthesia with intravenous injection of sodium pentobarbital (30 mg/kg).

2.6. Macroscopic Examination of Gastric Mucosa. Stomachs of anesthetized rats from each group were opened along the greater curvature and rinsed with normal saline (NaCl 0.9%) followed by gross examination for assessment of any abnormal lesions and then photographed. The length of each lesion in mm was measured according to Bozkurt et al. [26], and the gastric ulcer index (UI) was calculated according to the method described by Das and Banerjee [27].

2.7. Histological Screening of Gastric Mucosa. Stomachs were flushed with PBS pH 7.4 and fixed in 4% paraformaldehyde in 0.1 M phosphate buffer. Fixed specimens were processed using the conventional paraffin embedding technique including dehydration through ascending grades of ethanol and

TABLE 3: Phytochemical analysis of *S. persica* extract by GC-MS.

Retention time (min)	Phytochemicals	Area (%)
5.52	Chavicol	1.18
10.18	Oleic acid	1.97
12.31	3-Penten-2-one	4.24
15.58	Tris(trimethylsilyl) ether derivative of 1,25-dihydroxyvitamin D2	3.94
16.24	Retinoic acid	1.31
16.78	Palmitic acid	13.19
17.27	Androst-7-ene-6,17-dione	9.56
19.05	Methyl alpha-D-glucopyranoside	4.09
19.32	α -Linolenic acid	1.77
20.83	Tributyl acetyl citrate	5.24
23.78	Hexa-t-butylselenatrisiletane	6.97
26.33	Lycopene	16.56
27.45	Pregn-16-ene-11,14,18,20-tetrol	1.73
28.46	Lycoxanthin	1.61
	Ingredients less than 1.00%	26.64

clearing in 3 changes of xylene and melted paraffin and ended by embedding in paraffin wax at 65°C . Paraffin blocks were sectioned into $4 \mu\text{m}$ thickness sections. These sections were stained with hematoxylin and eosin (H&E) stain according to the method described by Bancroft and Layton [28] and Periodic acid-Schiff (PAS) stain according to Pearse [29]. The section images were taken with a digital camera (Leica EC3, Leica, Germany) connected to a microscope (Leica DM500).

2.8. Determination of Gastric Mucosal Malondialdehyde and Antioxidant Parameters. Gastric tissues were homogenized with PBS to prepare 10% (w/v) homogenate and divided into 3 aliquots; one was used for the estimation of the MDA level. The second aliquot was deproteinized by adding 10% trichloroacetic acid and centrifuged, and the supernatant was used for the determination of reduced glutathione level, while the third aliquot was centrifuged and used to determine the antioxidant enzyme activities in the supernatant. All procedures were performed using commercial kits (Biodiagnostic Co.) according to the manufacturer's instructions.

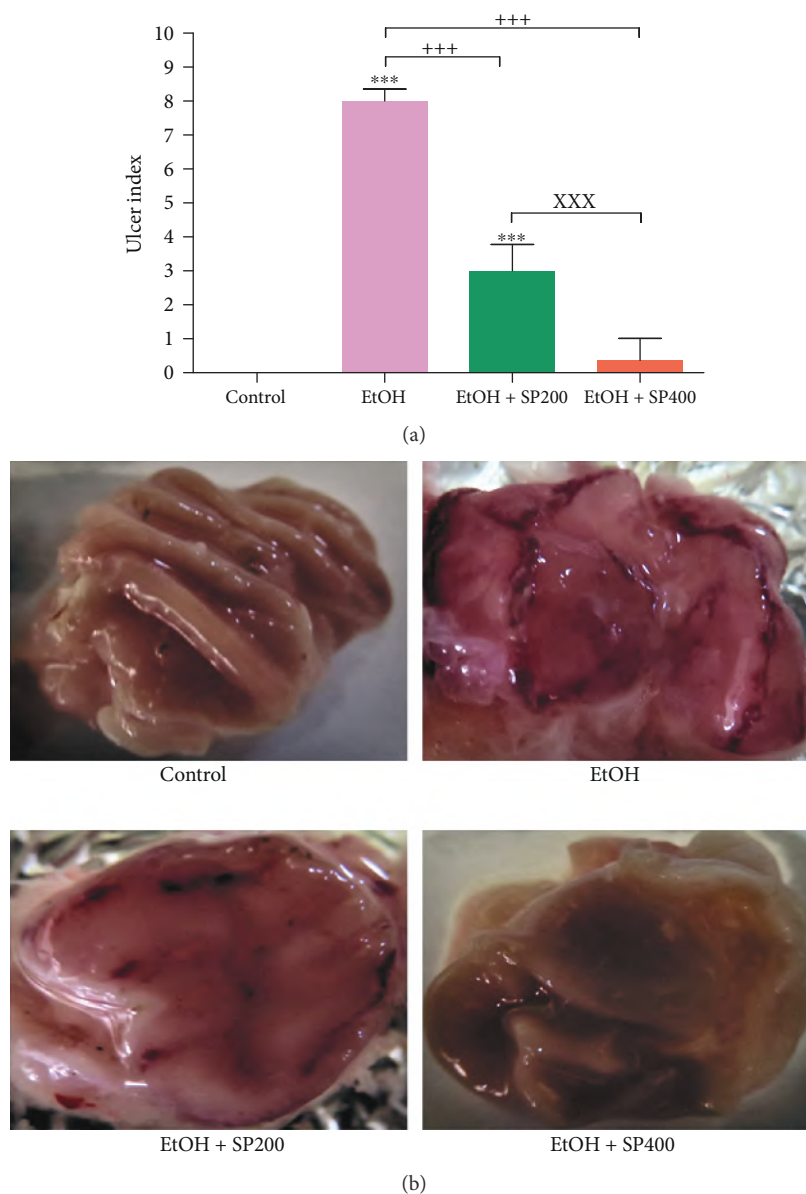


FIGURE 1: Gastric ulcer index (a) and macroscopic finding of gastric mucosal lesions (b) in rats exposed to ethanol-induced gastric ulcer and treated with *S. persica* extract. EtOH: ethanol-induced gastric ulcer; EtOH + SP200: ethanol-gastric ulcer treated with *S. persica* extract 200 mg/kg b.w.; EtOH + SP400: ethanol-gastric ulcer treated with *S. persica* extract 400 mg/kg b.w. Data are expressed as mean \pm SE ($n = 5$), and the statistical analysis was done with one-way ANOVA, followed by Tukey's post hoc test multiple comparisons. *** $P < 0.001$ versus control, + $P < 0.001$ versus EtOH, and XXX $P < 0.001$ versus EtOH + SP400.

2.9. Relative Expression of Proinflammatory Cytokine and Endothelial Nitric Oxide Synthase. Total RNA was isolated from 100 mg gastric tissue samples in all groups using an RNA extraction kit (Qiagen Inc., Germantown, MD, USA). qRT-PCR was performed in a real-time PCR machine using one-step SYBR Green RT-PCR Master Mix (Qiagen Inc.) and ready-made primers of TNF- α , IL-1 β , TGF- β 1, eNOS, and β -actin as housekeeping reference genes (Table 2). Thermal cycling conditions were retention time step at 50°C/10 min for cDNA synthesis followed by inactivation step at 95°C/15 min. For gene amplification, conditions were 45 cycles of 95°C/15 s, 58–60°C/30 s, and 60°C/1 min, followed

by 60°C/10 min. Analysis of relative gene expression was estimated using the $2^{-\Delta\Delta C_t}$ method [30].

2.10. Immunohistochemical Examination of Bax, iNOS, IL-1 β , and CD3 Proteins. Briefly, 4 μ m thick paraffin sections were prepared and deparaffinized using xylene, rehydrated in graded alcohols, and finally washed with distilled water. Antigen retrieval was done in the case of anti-iNOS, anti-Bax, and anti-CD3 by heating in 10 mM citrate buffer (pH 6.0) for 20 min at 95°C with no antigen retrieval for anti-IL-1 β , followed by washing with distilled water. Deactivation of endogenous peroxidase was carried out using 3%

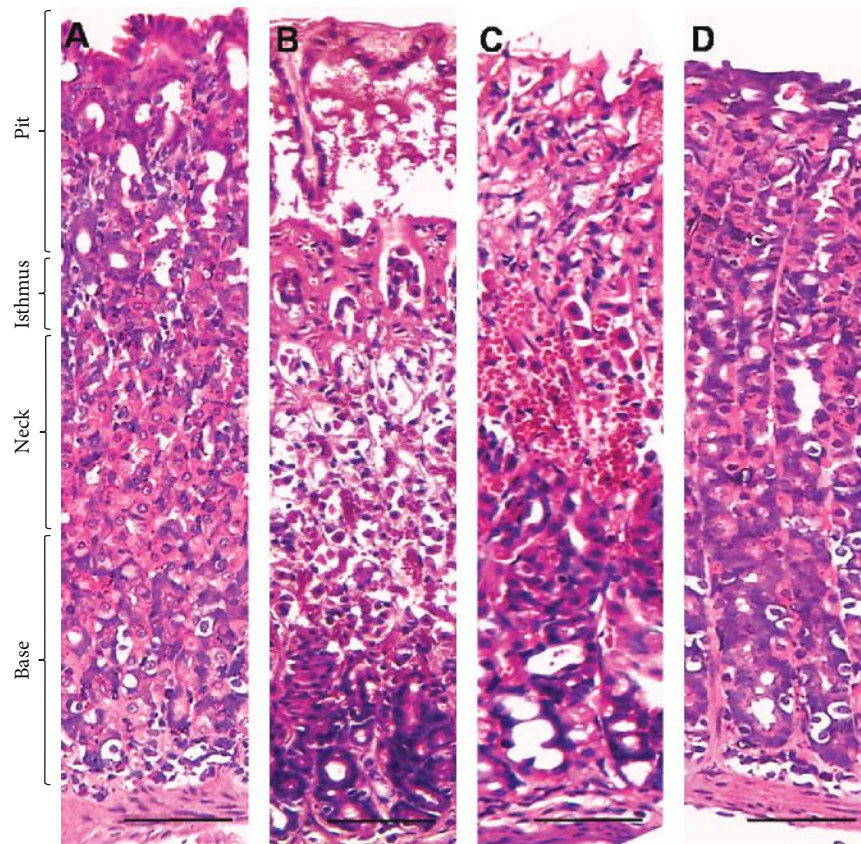


FIGURE 2: Light microscopic images of gastric mucosa. (a) The control group showed normal histologic appearance of all parts of the gastric wall. (b) The EtOH-induced gastric ulcer group revealed severe degeneration, necrosis, and hemorrhage of gastric base, neck, and isthmus with sloughing of gastric pits. (c) The EtOH-induced gastric ulcer and treated with *S. persica* at a dose of 200 mg/kg b.w. group showed moderated degeneration and hemorrhage in the gastric neck, isthmus, and pits with slight vacuolation in the gastric neck. (d) The EtOH-induced gastric ulcer and treated with *S. persica* at a dose of 400 mg/kg b.w. group showed normal histologic appearance of all gastric portions with only slight vacuolation. Scale bar = 50 μ m.

H₂O₂ in absolute methanol for 30 min at 4°C. After washing with PBS, the nonspecific reaction was blocked with 10% normal blocking serum for 60 min at room temperature. The sections were incubated at 4°C overnight with the specific primary antibody: monoclonal rabbit anti-human Bax antibody (Abcam, Cat: ab32503); polyclonal rabbit anti-mouse iNOS antibody (Abcam, Cat: ab15323, Cambridge, UK); polyclonal rabbit anti-mouse IL-1 β antibody (Abcam, Cat: ab9722); and polyclonal rabbit anti-human CD3 antibody (Abcam, Cat: ab5690) diluted in 1.5% BSA/PBS (pH7.2) at 1:100; 1:300; 1:250; and 1:100, respectively. For negative control sections, PBS was used instead of the primary antibody. After washing with PBS, the sections were incubated with biotin-conjugated goat anti-rabbit IgG antiserum (Histofine kit, Nichirei Corp.) for 60 min and then washed with PBS, followed by incubation with streptavidin-peroxidase conjugate (Histofine kit, Nichirei Corp.) for 30 min. The streptavidin-biotin complex was visualized with 3,3'-diaminobenzidine tetrahydrochloride (DAB) H₂O₂ solution, pH7.0, for 3 min. Then sections were washed in distilled water and Mayer's hematoxylin was used as a counterstain. The section images were taken with

a digital camera (Leica EC3, Leica, Germany) connected to a microscope (Leica DM500).

2.11. Statistical Analysis. Data were analyzed with one-way ANOVA followed by Tukey's post hoc test multiple comparisons using GraphPad Prism 5 (GraphPad Software, San Diego, CA, USA). The data of oxidative and antioxidant status were analyzed with one-way ANOVA followed by Duncan's post hoc test multiple comparisons using the SPSS programming tool (IBM SPSS, 201, Coppel, TX, USA).

3. Results

3.1. GC-MS Analysis of *S. persica* Extract. Phytochemical ingredients of SP extract detected with GC-MS analysis are listed in Table 3 and Figure S1. The SP extract contained many ingredients with antioxidant potentials such as lycopene (16.56%), α -linolenic acid (1.77%), oleic acid (1.97%), lycoxanthin (1.61%), and retinoic acid (1.31%).

3.2. Macroscopic Examination of Gastric Mucosa. Normal appearance of gastric mucosal epithelium and folding in the control group is shown in Figure 1. Rats exposed to EtOH

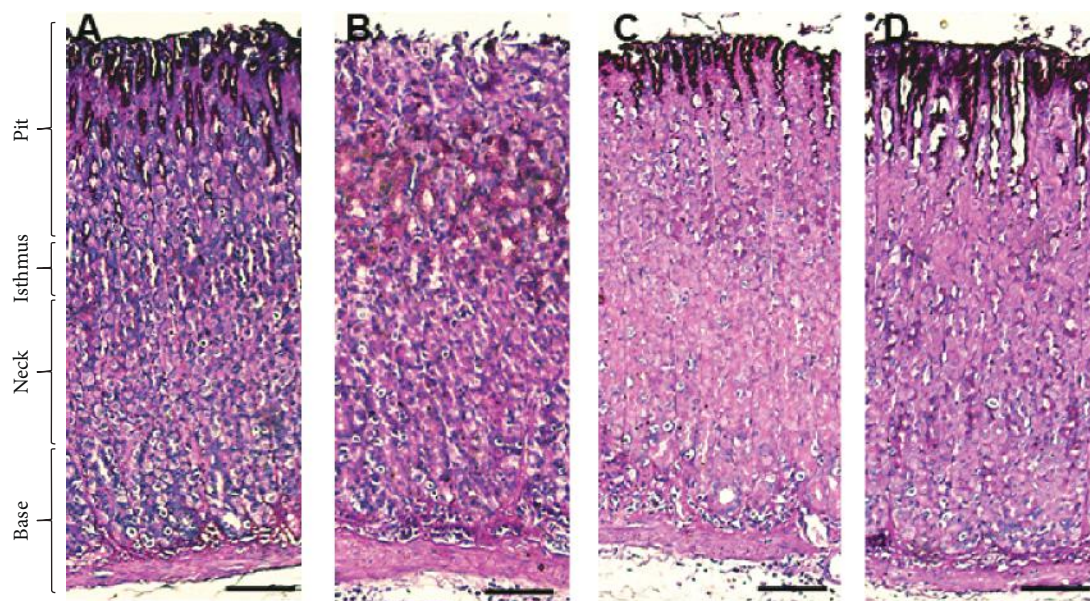


FIGURE 3: Light micrograph of histochemical staining of periodic acid–Schiff (PAS) in rats. (a) Control rats revealed intense PAS reaction at the surface mucous epithelium in the pit region. (b) No PAS reaction at the surface mucous epithelium in the pit region and moderate PAS reaction at the mucous cells in the pit and isthmus region of EtOH-induced gastric injury. (c) Lower distribution of PAS reacting cells in the SP200-protected group than those observed in the control group concentrated mainly in the pit region. (d) Similar distribution of PAS reacting cells in the SP400-protected group to the control group concentrated in the pit region. Scale bar = 50 μm .

TABLE 4: Oxidative stress and antioxidative profile in ethanol-induced gastric ulcer rat model pretreated with *S. persica* extract.

	MDA (nmol/g)	GSH ($\mu\text{mol/g}$)	T.SOD (U/g)	CAT (U/g)	GPX (U/g)	GST (U/g)
Control	101.3 \pm 8.2 ^a	16.8 \pm 1.6 ^c	75.4 \pm 7.8 ^c	11.2 \pm 2.6 ^c	46.9 \pm 7.6 ^c	143.2 \pm 12.4 ^c
EtOH	111.5 \pm 7.6 ^a	14.2 \pm 1.4 ^d	70.5 \pm 5.4 ^c	9.8 \pm 1.1 ^d	41.7 \pm 8.9 ^c	131.8 \pm 15.8 ^c
EtOH + SP200	83.7 \pm 8.9 ^b	18.6 \pm 2.1 ^b	85.4 \pm 7.1 ^b	13.6 \pm 2.3 ^b	63.8 \pm 8.7 ^b	165.7 \pm 13.3 ^b
EtOH + SP400	74.3 \pm 9.1 ^b	22.9 \pm 1.9 ^a	96.8 \pm 6.4 ^a	16.7 \pm 2.2 ^a	72.9 \pm 6.3 ^a	181.2 \pm 11.8 ^a

Values are expressed as mean \pm SEM. The means within the same column carrying different superscript letters are significantly different at $P < 0.05$ as determined with one-way ANOVA, followed by Duncan's post hoc test multiple comparisons. EtOH: ethanol-induced gastric ulcer group; EtOH + SP200: ethanol-induced gastric ulcer pretreated with *S. persica* extract at a dose of 200 mg/kg b.w.; EtOH + SP400: ethanol-induced gastric ulcer pretreated with *S. persica* extract at a dose of 400 mg/kg b.w.

revealed severe gastric mucosal congestion and hemorrhage, loose mucosal folds, and thinning and ballooning of the gastric wall with serious ulcers. However, treatment with SP extract significantly reduced the ethanol-induced gastric lesions, moderated congestion and petechial hemorrhage, improved the gastric mucosal folding, and lowered the ulcer index at an SP extract dose of 200 mg/kg, while the high dose of 400 mg/kg caused more alleviation in these lesions as compared to normal ones.

3.3. Histological Findings. Light microscopic examination of the gastric mucosa stained with H&E showed a normal structure of all gastric portions in the control group (Figure 2). Contrary to the control, ethanol produced gastric damage as manifested by intense degeneration, necrosis, and hemorrhages in almost all parts of the gastric wall, severe submucosal edema, and sloughing of gastric pits. Interestingly, treatment with SP extract significantly reduced the degeneration and hemorrhage induced by ethanol, indicating

protective action that was evident with the high dose of 400 mg/kg b.w.

An augmented level of PAS staining was observed at the surface of the mucosal epithelium in the pit region in the control group (Figure 3), indicating high glycoprotein contents. However, negative PAS staining of the surface mucosal epithelium showed low reactivity at the mucosa cells in the pit and isthmus regions among those in the alcohol-treated group. Notably, there was moderate distribution of PAS-reacting cells mainly at the pit region in SP200-treated rats, and an intense reaction was observed in SP400-treated rats resembling those in the control rats.

3.4. Oxidative Damage and Antioxidative Biomarkers. The levels of antioxidant GSH ($14.2 \pm 1.4 \mu\text{mol/g}$ tissue) and CAT ($9.8 \pm 1.1 \text{U/g}$ tissue) were significantly reduced in the EtOH group relative to control. Notably, SP extract intake in a dose-dependent manner significantly attenuated the gastric MDA level and motivated the enzymatic and

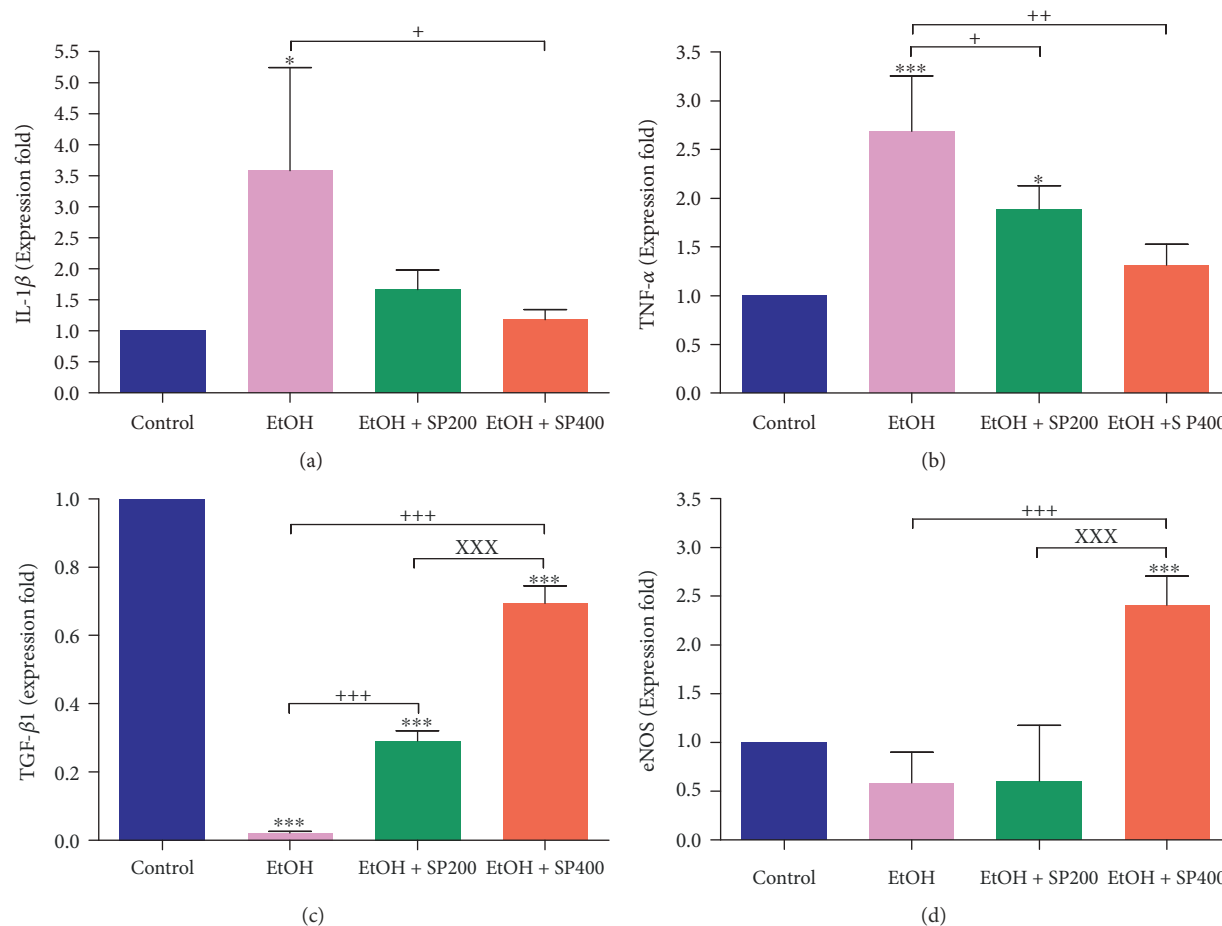


FIGURE 4: Reverse transcription polymerase chain reaction (RT-PCR) validation of (a) IL-1 β , (b) TNF- α , (c) TGF- β 1, and (d) eNOS. IL-1 β : interleukin-1 beta; TNF- α : tumor necrosis factor-alpha; TGF- β 1: transforming growth factor beta; eNOS: endothelial nitric oxide synthase; CON: control; EtOH: ethanol-treated group; EtOH + SP200: ethanol-treated and treated with *S. persica* at a dose of 200 mg/kg b.w.; EtOH + SP400: ethanol-treated and treated with *S. persica* at a dose of 400 mg/kg b.w. * $P < 0.05$ and *** $P < 0.001$ versus control. + $P < 0.05$, ++ $P < 0.01$, and +++ $P < 0.001$ versus EtOH. xxx $P < 0.001$ versus EtOH + SP400. Statistical analysis was done with one-way ANOVA, followed by Tukey's post hoc test multiple comparisons. Error bars represent SE. Samples ($n = 5$).

nonenzymatic antioxidant levels $P < 0.05$ when compared to EtOH-treated rats, suggesting antioxidative characteristics of the SP extract (Table 4).

3.5. Gastric IL-1 β , TNF- α , TGF- β 1, and eNOS Relative Expression. Ethanol intake significantly upregulated the proinflammatory cytokines' expression: TNF- α (2.7-fold) ($P < 0.001$) and IL-1 β (3.5-fold) ($P < 0.05$). It also reduced the expression of TGF- β 1 (0.02-fold) ($P < 0.001$) and insignificantly downregulated eNOS (0.6-fold), elucidating the inflammatory condition as compared to control (Figure 4). Pretreatment with SP extract significantly downregulated both proinflammatory cytokines in a dose-dependent manner comparable to the EtOH-treated group while causing an elevation in the relative expression of TGF- β 1 and eNOS $P < 0.001$, which is more pronounced at the high dose of SP extract in comparison to the control group.

3.6. Immunohistochemical Detection of Bax, iNOS, IL-1 β , and CD3 Proteins. Immunohistochemical analysis revealed an overexpression of Bax, IL-1 β , iNOS, and CD3 proteins in

the ethanol-treated group as indicated by high distribution of IL-1 β -, Bax-, and iNOS-immunopositive cells in the base, neck, isthmus, and mucous surface of the pit region as compared to negative or low distribution of immunopositive cells in the control group (Figures 5–7), while CD3-immunopositive cells distributed at the margin of the inflammation that was extensive in the alcohol group penetrated all epithelial layers (Figure 8). Interestingly, pretreatment with SP extract significantly reduced the immunopositive staining of IL-1 β , Bax, CD3, and eNOS in a dose-dependent manner in the EtOH group, elucidating reduced expression of these proteins.

4. Discussion

The current study highlights the antiulcerative effect of SP aqueous extract against EtOH-induced gastric ulceration in rats. This antiulcerative potential might be due to the antioxidant ingredients found in SP aqueous extract such as lycopene [31], α -linolenic acid [32], oleic acid [33], lycoxanthin [34], and retinoic acid [35].

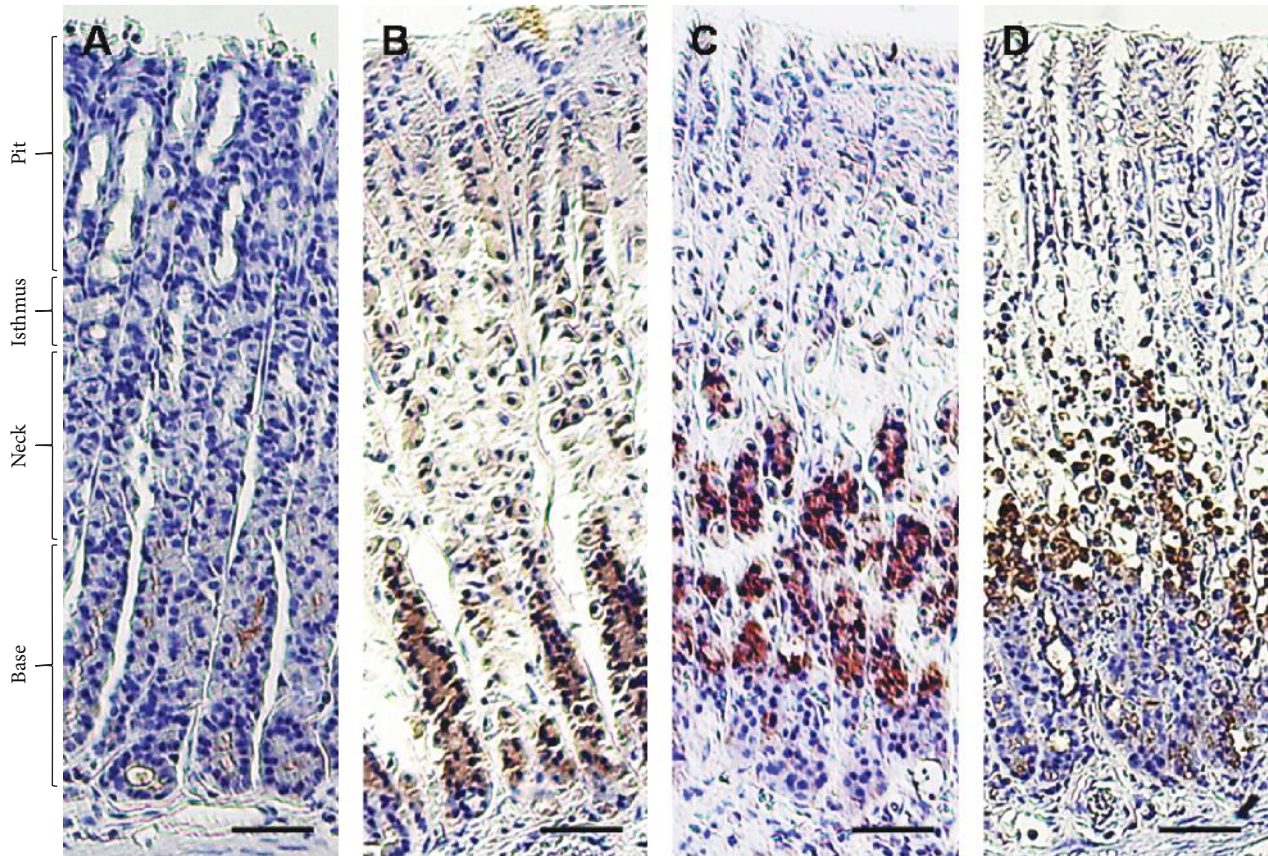


FIGURE 5: Immunohistochemical reactivity of Bax in rats exposed to induced gastric ulcer and treated with *S. persica* extract. (a) Control group, (b) EtOH-induced gastric ulcer group, (c) EtOH-induced gastric ulcer and treated with *S. persica* at a dose of 200 mg/kg b.w. group, and (d) EtOH-induced gastric ulcer and treated with *S. persica* at a dose of 400 mg/kg b.w. group. Scale bar = 50 μm .

Short-term exposure to ethanol-induced gastric damage, hemorrhagic erosions, and increased gastric ulcer index (UI) was confirmed by our histological findings: hemorrhagic degeneration, submucosal edema, shedding of gastric pits, and decreased glycoproteins in the gastric mucosal surface. These results are similar to those obtained by Yang et al. [36] who stated that ethanol had an immense effect on the gastric mucosa represented by severe hyperemia, inflammatory cell infiltration, loss of epithelial cells, and cell erosions. In addition to hemorrhage, epithelial exfoliation, submucosal edema [37], and mucosal friability [38] were recognized. In a recent study, interrupted gastric mucosa, neutrophil infiltration, glandular cell nuclear intensification, and acute hemorrhage were the major histological findings following ethanol exposure in rats [39].

The collective mechanisms implicated in the gastric damaging effect induced by ethanol are due to the perturbation of the antioxidant system, recruitment of inflammatory cascade and apoptosis, and disturbance of nitric oxide synthases. Results of the present study revealed that ethanol stimulated slight production of MDA accompanied by the minimization of both enzymatic and nonenzymatic antioxidants in gastric tissues. Antonisamy et al. [5] revealed that the imbalance between prooxidant and antioxidant molecules is the major contributor of ethanol-induced gastric damage. Park et al. [25] reported that ethanol had dual effects on the gastric

mucosa: direct action through damaging the mucosal membranes, cytotoxic dehydration, and generation of inflammatory signaling pathways and an indirect action via neutrophil infiltration with subsequent inflammation and induction of oxidative stress and apoptosis. Alcohol consumption catalyzed the formation of MDA in the gastric tissue with a reduction in SOD, CAT enzymatic activities [40], and GPX activity [41]. Treatment with SP extract caused a decline in the gastric MDA level and enhanced the enzymatic and nonenzymatic antioxidants. The antioxidant activity of SP may be attributed to its high content of furan derivatives, vitamin C, tannins, saponins, and flavonoids [42, 43].

The data of the current study showed an upregulation of gene expression of proinflammatory cytokines: TNF- α and IL-1 β in the gastric mucosa of the EtOH-treated rats. In the same context, Katary and Salahuddin [44] reported the enhancement of gene expression and mucosal levels of TNF- α along with increased mucosal levels of IL-1 β after ethanol consumption in rats. The gastric inflammatory condition has been associated with the release of TNF- α , which activates the immune cells and other proinflammatory cytokines and increases the NF- κB expression [45]. TNF- α could trigger gastric tissue damage mediated through the activation of neutrophil migration into the gastric tissue associated with retardation of gastric ulcer healing [37]. Inevitably, alcohol resulted in the augmentation of the proinflammatory

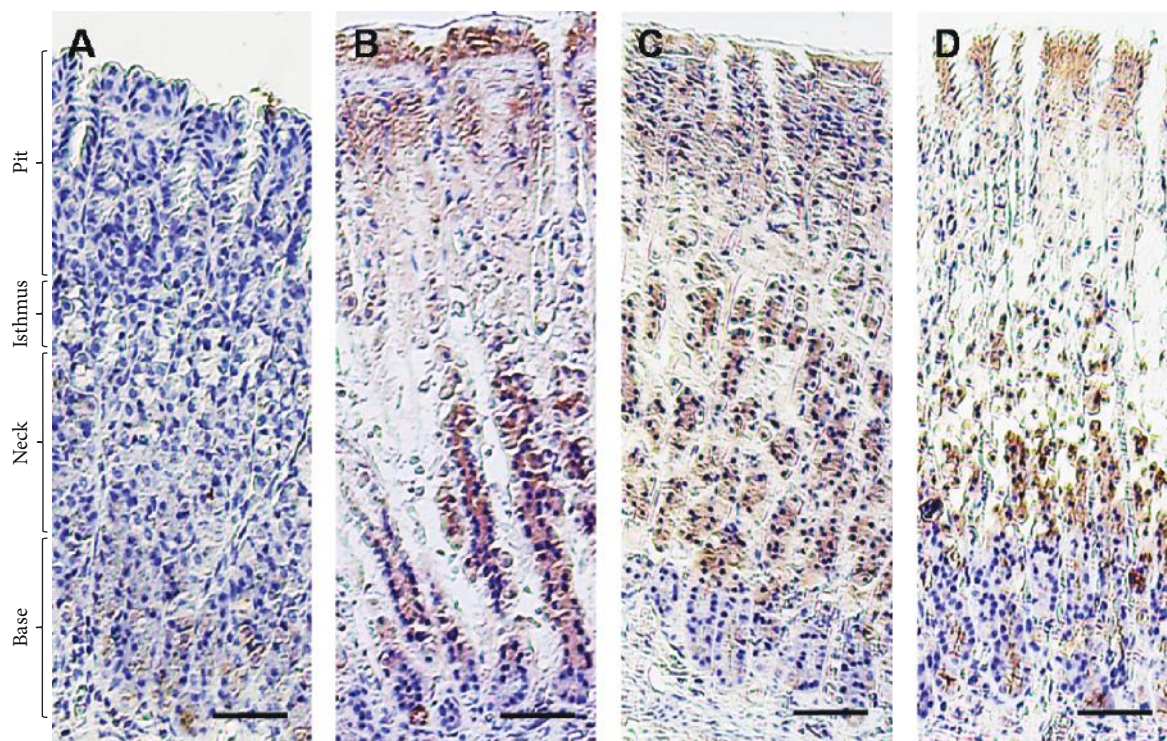


FIGURE 6: Immunohistochemical reactivity of iNOS in rats exposed to induced gastric ulcer and treated with *S. persica* extract. (a) Control group, (b) EtOH-induced gastric ulcer group, (c) EtOH-induced gastric ulcer and treated with *S. persica* at a dose of 200 mg/kg b.w. group, and (d) EtOH-induced gastric ulcer and treated by *S. persica* at a dose of 400 mg/kg b.w. group. Scale bar = 50 μ m.

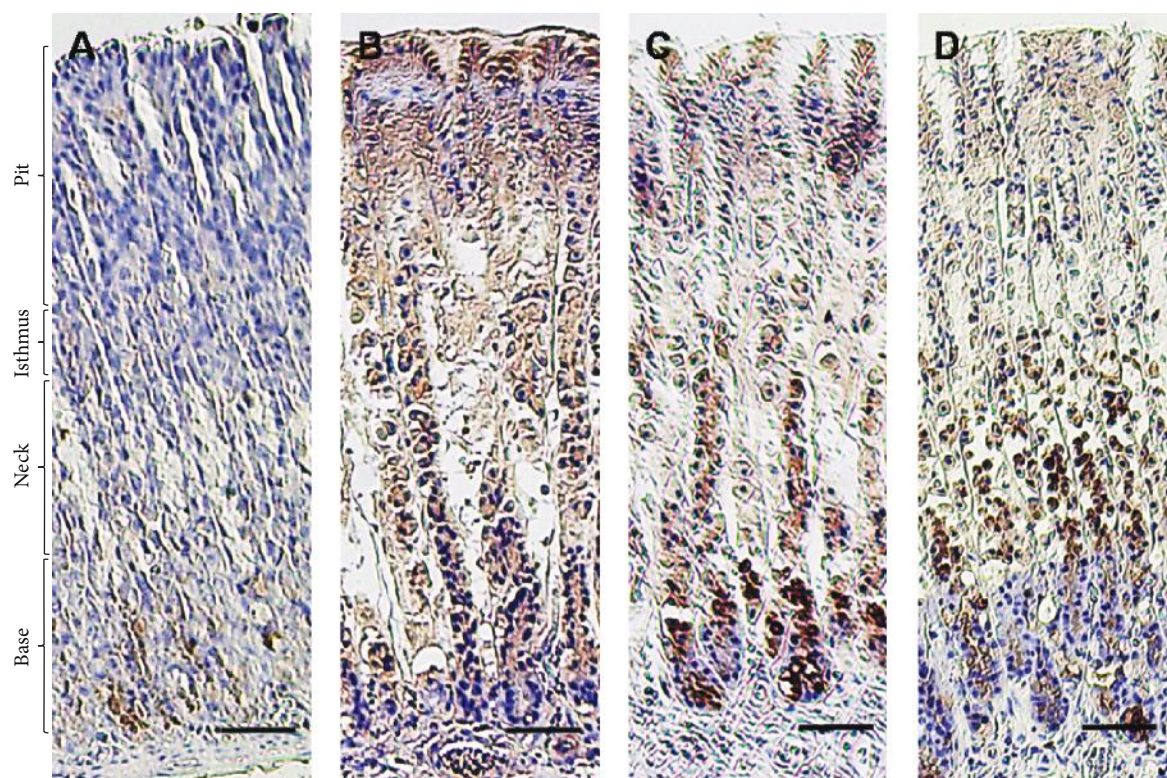


FIGURE 7: Immunohistochemical reactivity of IL-1 β in rats exposed to induced gastric ulcer and treated with *S. persica* extract. (a) Control group, (b) EtOH-induced gastric ulcer group, (c) EtOH-induced gastric ulcer and treated with *S. persica* at a dose of 200 mg/kg b.w. group, and (d) EtOH-induced gastric ulcer and treated with *S. persica* at a dose of 400 mg/kg b.w. group. Scale bar = 50 μ m.

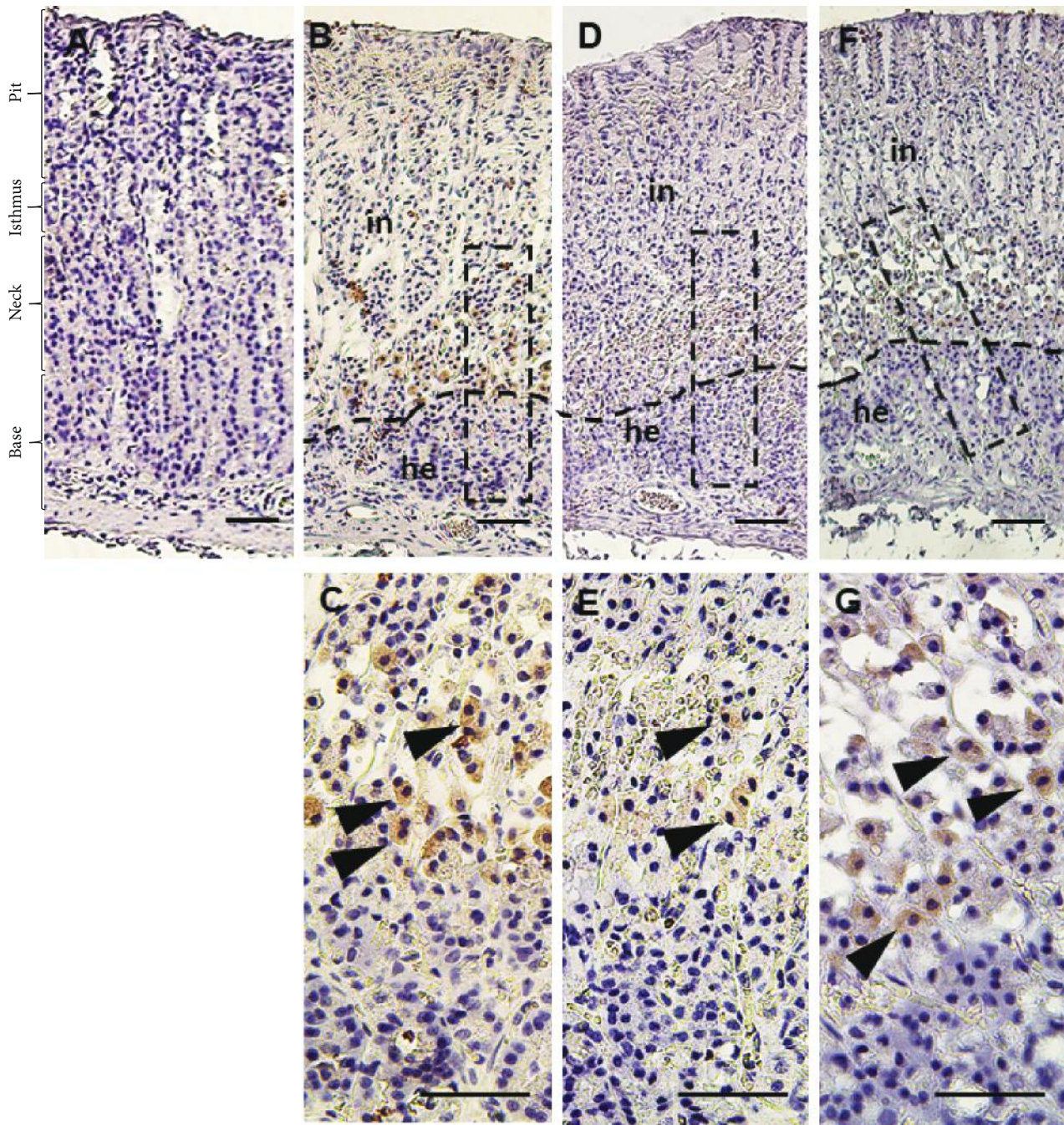


FIGURE 8: Immunohistochemical reactivity of CD3 in rats exposed to induced gastric ulcer and treated with *S. persica* extract. (a) Control group, (b-c) EtOH-induced gastric ulcer group, (d-e) EtOH-induced gastric ulcer and treated with *S. persica* at a dose of 200 mg/kg b.w. group, and (f-g) EtOH-induced gastric ulcer and treated with *S. persica* at a dose of 400 mg/kg b.w. group. Scale bar = 50 μ m.

cytokines: TNF- α participating in gastric ulcer via boosting apoptosis, NF- κ B, iNOS, and neutrophil infiltration and IL-1 β arousing the oxidative stress inflicting the gastric damage [46]. Meanwhile, TNF- α promotes the release of oxygen free radicals and other proinflammatory cytokines, causing destruction of cell membrane stability and leading to gastric tissue injuries [36].

TGF- β 1 coordinates different signaling pathways including adhesion, cell proliferation, angiogenesis, and production

of extracellular matrix components [47]. Our data revealed low expression of TGF- β 1 in the EtOH-treated group, while SP extract mitigated the inflammatory effect of ethanol on the gastric tissue, which is in compliance with the results of Monforte et al. [17] who showed that the antiulcer activity of SP decoction against acetylsalicylic acid-induced gastric ulcer in rats resulted in a significant reduction of UI via anti-inflammatory activity. Furthermore, the serum proinflammatory cytokine IL-1 β , IL-6, and TNF- α levels

were significantly decreased following the administration of ethyl acetate extract of SP in a gastric ulcer model [20].

Apoptosis induction was evidenced in the current study by increased protein expression of the proapoptotic Bax after EtOH exposure. Ye et al. [48] reported that the gastric damage induced by ethanol might be due, to a certain extent, to the enhancement of the apoptotic pathway. The proapoptotic protein Bax signals the initiation of apoptosis [4], causing cytochrome-C release followed by caspase cascade activation and finally apoptotic cell death [49]. Notably, Al Batran et al. [50] implied that ethanol-triggered gastric injury was in part due to the enhancement of apoptosis in subsequent mucosal epithelial cell loss. The attenuation of lipid peroxidation and TNF- α secretion resulted in inhibition of the gastric apoptosis [4]. The anti-oxidative and anti-inflammatory activities of SP reflected the inhibition of the apoptotic pathway, providing another explanation of its antiulcer activity.

Ethanol evoked the protein expression of iNOS and the decline of the gene expression of eNOS in gastric tissue. A high concentration of NO generated from iNOS was involved in the gut tissue damage during the inflammatory conditions [51]. Nagai et al. [52] indicated that iNOS-produced NO had a critical role in the enhancement of gastric ulcer. Activation of iNOS expression was associated with gastric ulcer and chronic ulcerative colitis in affected patients, suggesting a detrimental effect due to the excessive production of NO on the pathogenesis of these conditions [53]. In contrast, eNOS-derived NO plays a central role in gastric ulcer healing via the maintenance of gastric epithelium, mucosal blood flow, and mucus secretion and synthesis [54]. The present results are comparable to those of Pan et al. [55] who reported that ethanol activated iNOS and the inhibitory effect on eNOS gene expression. Furthermore, ethanol provoked the gene expression of TNF- α , IL-1 β , and iNOS, inflicting the immense effect of the generated NO on gastric ulcer formation [56]. This phenomenon was initiated via the NF- κ B pathway where the production of proinflammatory cytokines TNF- α and IL-1 β , upregulation of iNOS gene expression, and release of NO were enhanced by activated NF- κ B during gastric ulcer formation [57]. However, pretreatment with SP extract significantly reduced the protein expression of iNOS and upregulated eNOS gene expression in gastric tissue exposed to EtOH, indicating an antiulcerative effect. NO derived from highly expressed iNOS in the ulcerated stomach had no role in the healing process modulation. On the contrary, eNOS-originated NO might enhance the formation of new blood vessels assisting the gastric ulcer healing [11]. This hypothesis suggested the involvement of NO generated from eNOS isoforms in the healing process of gastric ulcers. This mechanism emphasizes the pivotal role that NO plays in the liberation of vasoactive peptides and in the stimulation of cGMP in gastric tissue [58]. NO-stimulated cGMP led to relaxation of mouse gastric smooth muscles and prevented the cytotoxic effect of EtOH on the gastric parietal cells [59]. Also, eNOS-originated NO established the protection and healing of gastric ulcer via augmentation of mucus and bicarbonate secretions, promotion of blood flow, and angiogenesis [60]. CD3 proteins are receptors characteristic

for T lymphocyte populations. Bamford et al. [61] detected an increase of CD3 expression in gastric inflammation caused by infection of *H. pylori*. Our results showed the increase of intensity of CD3-expressed cells in the EtOH-treated group that decreased in the SP-treated groups suggesting the effective role of SP in decreasing the symptoms of inflammation that resulted from alcohol exposure. This supports our histological PAS staining that was used to evaluate the level of glycoprotein, mucin, and subsequent mucus content; intense mucin staining in the mucosal cell layer reflects high mucus content in the SP-treated groups, suggesting a protective effect.

5. Conclusion

SP aqueous extract alleviated serious gastric mucosal ulcerations induced by ethanol and emphasized its efficacy as an antiulcer protectant. The underlying mechanism of its activity is through the enhancement of the antioxidative defense system, minimization of proinflammatory cytokines and apoptotic pathway, augmentation of mucus content, and redesign of the NOS isoforms supporting the antioxidant, anti-inflammatory, and antiapoptotic effects of SP favoring the healing and prevention of gastric ulcers.

Data Availability

All data generated or analyzed during this study are included in this article and its supplementary information files.

Ethical Approval

The experiments were done following the Ethics Committee recommendations at the Faculty of Veterinary Medicine, Alexandria University, Egypt.

Conflicts of Interest

The authors declare that they have no competing interests.

Authors' Contributions

Mohamed A. Lebda, Ali H. El-Far, Ahmed E. Noreldin, and Yaser H. A. Elewa contributed equally to the experimental design, experimental work, data analysis, manuscript writing, and manuscript revisions. Shaker A. Mousa and Soad K. Al Jaouni contributed to the design, manuscript writing, and manuscript revisions.

Acknowledgments

The authors express many thanks to Kelly A. Keating (Pharmaceutical Research Institute, Albany College of Pharmacy and Health Sciences) for the brilliant language revision.

Supplementary Materials

Figure S1: GC-MS chromatogram showing the area % of *S. persica* extract phytoconstituents at different retention times. (*Supplementary Materials*)

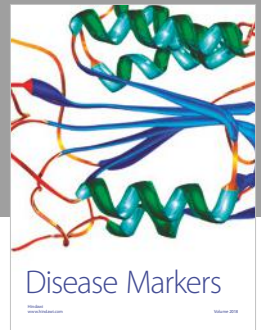

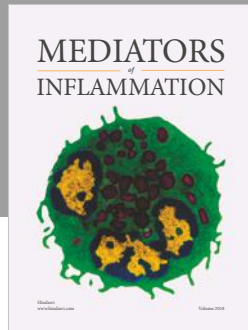
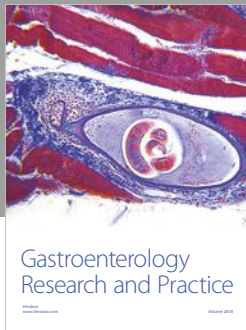
References

- [1] L. Laine, K. Takeuchi, and A. Tarnawski, "Gastric mucosal defense and cytoprotection: bench to bedside," *Gastroenterology*, vol. 135, no. 1, pp. 41–60, 2008.
- [2] J. M. Kang, P. J. Seo, N. Kim et al., "Analysis of direct medical care costs of peptic ulcer disease in a Korean tertiary medical center," *Scandinavian Journal of Gastroenterology*, vol. 47, no. 1, pp. 36–42, 2011.
- [3] Y.-F. Zheng, J.-H. Xie, Y.-F. Xu et al., "Gastroprotective effect and mechanism of patchouli alcohol against ethanol, indomethacin and stress-induced ulcer in rats," *Chemico-Biological Interactions*, vol. 222, pp. 27–36, 2014.
- [4] S. I. Abdelwahab, "Protective mechanism of gallic acid and its novel derivative against ethanol-induced gastric ulcerogenesis: involvement of immunomodulation markers, Hsp70 and Bcl-2-associated X protein," *International Immunopharmacology*, vol. 16, no. 2, pp. 296–305, 2013.
- [5] P. Antonisamy, P. Subash-Babu, A. Albert-Baskar et al., "Experimental study on gastroprotective efficacy and mechanisms of luteolin-7-O-glucoside isolated from *Ophiorrhiza mungos* Linn. in different experimental models," *Journal of Functional Foods*, vol. 25, pp. 302–313, 2016.
- [6] W.-c. Zhao, Y.-s. Xu, G. Chen, Y. Guo, D.-y. Wang, and G.-b. Meng, "*Veronicastrum axillare* alleviates ethanol-induced injury on gastric epithelial cells via downregulation of the NF- κ B signaling pathway," *Gastroenterology Research and Practice*, vol. 2017, Article ID 7395032, 8 pages, 2017.
- [7] X. Chang, F. Luo, W. Jiang et al., "Protective activity of salidroside against ethanol-induced gastric ulcer via the MAPK/NF- κ B pathway in vivo and in vitro," *International Immunopharmacology*, vol. 28, no. 1, pp. 604–615, 2015.
- [8] D. Laloo, S. K. Prasad, S. Krishnamurthy, and S. Hemalatha, "Gastroprotective activity of ethanolic root extract of *Potentilla fulgens* Wall. ex Hook," *Journal of Ethnopharmacology*, vol. 146, no. 2, pp. 505–514, 2013.
- [9] X. Mei, D. Xu, S. Xu, Y. Zheng, and S. Xu, "Novel role of Zn(II)-curcumin in enhancing cell proliferation and adjusting proinflammatory cytokine-mediated oxidative damage of ethanol-induced acute gastric ulcers," *Chemico-Biological Interactions*, vol. 197, no. 1, pp. 31–39, 2012.
- [10] P. Antonisamy, P. Subash-Babu, A. A. Alshatwi et al., "Gastroprotective effect of nymphayol isolated from *Nymphaea stellata* (Willd.) flowers: contribution of antioxidant, anti-inflammatory and anti-apoptotic activities," *Chemico-Biological Interactions*, vol. 224, pp. 157–163, 2014.
- [11] L. Ma and J. L. Wallace, "Endothelial nitric oxide synthase modulates gastric ulcer healing in rats," *American Journal of Physiology-Gastrointestinal and Liver Physiology*, vol. 279, no. 2, pp. G341–G346, 2000.
- [12] C. H. Cho, "Current roles of nitric oxide in gastrointestinal disorders," *Journal of Physiology-Paris*, vol. 95, no. 1–6, pp. 253–256, 2001.
- [13] H. Suo, X. Zhao, Y. Qian et al., "Lactobacillus fermentum Suo attenuates HCl/ethanol induced gastric injury in mice through its antioxidant effects," *Nutrients*, vol. 8, no. 3, p. 155, 2016.
- [14] A. S. Tarnawski, "Cellular and molecular mechanisms of gastrointestinal ulcer healing," *Digestive Diseases and Sciences*, vol. 50, Supplement 1, pp. S24–S33, 2005.
- [15] L. Pinheiro Silva, C. Damacena de Angelis, F. Bonamin et al., "*Terminalia catappa* L.: a medicinal plant from the Caribbean pharmacopeia with anti-*Helicobacter pylori* and antiulcer action in experimental rodent models," *Journal of Ethnopharmacology*, vol. 159, pp. 285–295, 2015.
- [16] P. Salehi and S. H. Momeni Danaie, "Comparison of the antibacterial effects of persica mouthwash with chlorhexidine on *Streptococcus mutans* in orthodontic patients," *DARU Journal of Pharmaceutical Sciences*, vol. 14, no. 4, pp. 178–182, 2006.
- [17] M. T. Monforte, N. Miceli, M. R. Mondello, R. Sanogo, A. Rossitto, and E. M. Galati, "Antiulcer activity of *Salvadora persica* on experimental ASA-induced ulcer in rats: ultrastructural modifications," *Pharmaceutical Biology*, vol. 39, no. 4, pp. 289–292, 2008.
- [18] G. A. Soliman, M. A. Ganaie, H. N. Althurwi, F. F. Albaqami, M. A. Salkini, and M. S. Abdel-Kader, "Extract of *Salvadora persica* roots attenuates lead acetate-induced testicular oxidative stress in rats," *Journal of Pharmacy & Pharmacognosy Research*, vol. 5, no. 4, pp. 238–250, 2017.
- [19] M. Nomani, M. J. Hosseini, M. Vazirian, A. Nomani, and H. R. Monsef-Esfahani, "Evaluation of anti-inflammatory effect of *Salvadora persica* in IBD-induced rat," *Research Journal of Pharmacognosy*, vol. 4, p. 27, 2017.
- [20] A. Y. Ibrahim, S. E. el-Gengaihi, H. M. Motawea, and A. A. Sleem, "Anti-inflammatory activity of *Salvadora persica* L. against carrageenan induced paw oedema in rat relevant to inflammatory cytokines," *Notulae Scientia Biologicae*, vol. 3, no. 4, pp. 22–28, 2011.
- [21] A.-M. Fouda and A. R. Youssef, "Antiosteoporotic activity of *Salvadora persica* sticks extract in an estrogen deficient model of osteoporosis," *Osteoporosis and Sarcopenia*, vol. 3, no. 3, pp. 132–137, 2017.
- [22] R. Albabtain, M. Azeem, Z. Wondimu, T. Lindberg, A. K. Borg-Karlson, and A. Gustafsson, "Investigations of a possible chemical effect of *Salvadora persica* chewing sticks," *Evidence-Based Complementary and Alternative Medicine*, vol. 2017, Article ID 2576548, 10 pages, 2017.
- [23] M. S. Hooda, R. Pal, A. Bhandari, and J. Singh, "Antihyperglycemic and antihyperlipidemic effects of *Salvadora persica* in streptozotocin-induced diabetic rats," *Pharmaceutical Biology*, vol. 52, no. 6, pp. 745–749, 2014.
- [24] W. Filimban, N. ElSawy, E. A. Header, and M. El-Boshy, "Evaluation of aqueous extract of *Salvadora persica* and *Glycyrrhiza glabra* in treatment of gastric ulcer," *Jokull Journal*, vol. 65, no. 5, pp. 275–293, 2015.
- [25] S. W. Park, T. Y. Oh, Y. S. Kim et al., "*Artemisia asiatica* extracts protect against ethanol-induced injury in gastric mucosa of rats," *Journal of Gastroenterology and Hepatology*, vol. 23, no. 6, pp. 976–984, 2008.
- [26] A. Bozkurt, M. Yuksel, G. Haklar, H. Kurtel, B. C. Yegen, and I. Alican, "Adenosine protects against indomethacin-induced gastric damage in rats," *Digestive Diseases and Sciences*, vol. 43, no. 6, pp. 1258–1263, 1998.
- [27] D. Das and R. K. Banerjee, "Effect of stress on the antioxidant enzymes and gastric ulceration," *Molecular and Cellular Biochemistry*, vol. 125, no. 2, pp. 115–125, 1993.
- [28] J. D. Bancroft and C. Layton, "The hematoxylin and eosin," in *Theory Practice of Histological Techniques*, S. K. Suvarna, C. Layton, and J. D. Bancroft, Eds., Churchill Livingstone of El Sevier, Philadelphia, PA, USA, 7th edition, 2013.
- [29] A. G. E. Pearse, *Histochemistry, Theoretical and Applied, Preparative and Optical Technology*, Churchill-Livingstone, Edinburgh, 4th edition, 1980.

- [30] J. S. Yuan, A. Reed, F. Chen, and C. N. Stewart Jr., "Statistical analysis of real-time PCR data," *BMC Bioinformatics*, vol. 7, no. 1, p. 85, 2006.
- [31] C. Hanson, E. Lyden, J. Furtado et al., "Serum lycopene concentrations and associations with clinical outcomes in a cohort of maternal-infant dyads," *Nutrients*, vol. 10, no. 2, p. 204, 2018.
- [32] É. Fortin, R. Blouin, J. Lapointe, H. V. Petit, and M.-F. Palin, "Linoleic acid, α -linolenic acid and enterolactone affect lipid oxidation and expression of lipid metabolism and antioxidant-related genes in hepatic tissue of dairy cows," *British Journal of Nutrition*, vol. 117, no. 09, pp. 1199–1211, 2017.
- [33] J. S. Perona, C. Arcemis, V. Ruiz-Gutierrez, and A. Catala, "Effect of dietary high-oleic-acid oils that are rich in antioxidants on microsomal lipid peroxidation in rats," *Journal of Agricultural and Food Chemistry*, vol. 53, no. 3, pp. 730–735, 2005.
- [34] Y. Bellik, L. Boukraâ, H. Alzahrani et al., "Molecular mechanism underlying anti-inflammatory and anti-allergic activities of phytochemicals: an update," *Molecules*, vol. 18, no. 1, pp. 322–353, 2013.
- [35] R. Edge and T. Truscott, "Singlet oxygen and free radical reactions of retinoids and carotenoids—a review," *Antioxidants*, vol. 7, no. 1, p. 5, 2018.
- [36] Y. Yang, B. Yin, L. Lv et al., "Gastroprotective effect of aucubin against ethanol-induced gastric mucosal injury in mice," *Life Sciences*, vol. 189, pp. 44–51, 2017.
- [37] K. Amirshahrokhi and A.-R. Khalili, "The effect of thalidomide on ethanol-induced gastric mucosal damage in mice: involvement of inflammatory cytokines and nitric oxide," *Chemico-Biological Interactions*, vol. 225, pp. 63–69, 2015.
- [38] M. Umamaheswari, K. AsokKumar, A. Somasundaram, T. Sivashanmugam, V. Subhadra Devi, and T. K. Ravi, "Xanthine oxidase inhibitory activity of some Indian medical plants," *Journal of Ethnopharmacology*, vol. 109, no. 3, pp. 547–551, 2007.
- [39] Y. Zhang, H. Wang, N. Mei et al., "Protective effects of polysaccharide from *Dendrobium nobile* against ethanol-induced gastric damage in rats," *International Journal of Biological Macromolecules*, vol. 107, Part A, pp. 230–235, 2018.
- [40] C. Xu, C. Ding, N. Zhou, X.-M. Ruan, and B.-X. Guo, "A polysaccharide from *Aloe vera* L. var. *chinensis* (Haw.) Berger prevents damage to human gastric epithelial cells in vitro and to rat gastric mucosa in vivo," *Journal of Functional Foods*, vol. 24, pp. 501–512, 2016.
- [41] A. Paulrayer, A. Adithan, J. Lee et al., "Aronia melanocarpa (black chokeberry) reduces ethanol-induced gastric damage via regulation of HSP-70, NF- κ B, and MCP-1 signaling," *International Journal of Molecular Sciences*, vol. 18, no. 6, p. 1195, 2017.
- [42] S. A. Mohamed and J. A. Khan, "Antioxidant capacity of chewing stick miswak *Salvadora persica*," *BMC Complementary and Alternative Medicine*, vol. 13, no. 1, 2013.
- [43] M. A. Farag, S. Fahmy, M. A. Choucry, M. O. Wahdan, and M. F. Elsebai, "Metabolites profiling reveals for antimicrobial compositional differences and action mechanism in the toothbrushing stick "miswak" *Salvadora persica*," *Journal of Pharmaceutical and Biomedical Analysis*, vol. 133, pp. 32–40, 2017.
- [44] M. A. Katary and A. Salahuddin, "Gastroprotective effect of punicalagin against ethanol-induced gastric ulcer: the possible underlying mechanisms," *Biomarkers Journal*, vol. 3, p. 3, 2017.
- [45] S. K. Yadav, B. Adhikary, S. Chand, B. Maity, S. K. Bandyopadhyay, and S. Chattopadhyay, "Molecular mechanism of indomethacin-induced gastropathy," *Free Radical Biology & Medicine*, vol. 52, no. 7, pp. 1175–1187, 2012.
- [46] S. Verma and V. L. Kumar, "Attenuation of gastric mucosal damage by artesunate in rat: modulation of oxidative stress and NF κ B mediated signaling," *Chemico-Biological Interactions*, vol. 257, pp. 46–53, 2016.
- [47] P. Shang, W. Liu, T. Liu et al., "Acetyl-11-keto- β -boswellic acid attenuates prooxidant and profibrotic mechanisms involving transforming growth factor- β 1, and improves vascular remodeling in spontaneously hypertensive rats," *Scientific Reports*, vol. 6, no. 1, 2016.
- [48] H.-H. Ye, K.-J. Wu, S.-J. Fei et al., "Propofol participates in gastric mucosal protection through inhibiting the toll-like receptor-4/nuclear factor kappa-B signaling pathway," *Clinics and Research in Hepatology and Gastroenterology*, vol. 37, no. 1, pp. e3–e15, 2013.
- [49] X.-J. Luo, B. Liu, Z. Dai et al., "Expression of apoptosis-associated microRNAs in ethanol-induced acute gastric mucosal injury via JNK pathway," *Alcohol*, vol. 47, no. 6, pp. 481–493, 2013.
- [50] R. Al Batran, F. Al-Bayaty, M. M. Jamil Al-Obaidi et al., "In vivo antioxidant and antiulcer activity of *Parkia speciosa* ethanolic leaf extract against ethanol-induced gastric ulcer in rats," *PLoS One*, vol. 8, no. 5, article e64751, 2013.
- [51] M. D. Barrachina, J. P. Panes, and J. V. Esplugues, "Role of nitric oxide in gastrointestinal inflammatory and ulcerative diseases: perspective for drugs development," *Current Pharmaceutical Design*, vol. 7, no. 1, pp. 31–48, 2001.
- [52] N. Nagai, T. Fukuhata, Y. Ito, S. Usui, and K. Hirano, "Involvement of interleukin 18 in indomethacin-induced lesions of the gastric mucosa in adjuvant-induced arthritis rat," *Toxicology*, vol. 255, no. 3, pp. 124–130, 2009.
- [53] W. Li, H. Huang, X. Niu, T. Fan, Q. Mu, and H. Li, "Protective effect of tetrahydrocoptisine against ethanol-induced gastric ulcer in mice," *Toxicology and Applied Pharmacology*, vol. 272, no. 1, pp. 21–29, 2013.
- [54] Y. Li, W. P. Wang, H. Y. Wang, and C. H. Cho, "Intragastric administration of heparin enhances gastric ulcer healing through a nitric oxide-dependent mechanism in rats," *European Journal of Pharmacology*, vol. 399, no. 2-3, pp. 205–214, 2000.
- [55] L.-r. Pan, Q. Tang, Q. Fu, B.-r. Hu, J.-z. Xiang, and J.-q. Qian, "Roles of nitric oxide in protective effect of berberine in ethanol-induced gastric ulcer mice1," *Acta Pharmacologica Sinica*, vol. 26, no. 11, pp. 1334–1338, 2005.
- [56] J.-W. Song, C.-S. Seo, T.-I. Kim et al., "Protective effects of Manassantin A against ethanol-induced gastric injury in rats," *Biological & Pharmaceutical Bulletin*, vol. 39, no. 2, pp. 221–229, 2016.
- [57] S. A. El-Maraghy, S. M. Rizk, and N. N. Shahin, "Gastroprotective effect of crocin in ethanol-induced gastric injury in rats," *Chemico-Biological Interactions*, vol. 229, pp. 26–35, 2015.
- [58] X. E. Yu and Q. N. Luo, "Protective effects of exogenous nitric oxide on acid-ethanol induced gastric ulcer in Guinea-pig," *World Chinese Journal of Digestology*, vol. 8, p. 224, 2000.
- [59] D. Jimenez, M. J. Martin, D. Pozo et al., "Mechanisms involved in protection afforded by L-arginine in ibuprofen-induced

gastric damage: role of nitric oxide and prostaglandins," *Digestive Diseases and Sciences*, vol. 47, no. 1, pp. 44–53, 2002.

- [60] L. Zhang, J. W. Ren, C. C. M. Wong et al., "Effects of cigarette smoke and its active components on ulcer formation and healing in the gastrointestinal mucosa," *Current Medicinal Chemistry*, vol. 19, no. 1, pp. 63–69, 2012.
- [61] K. B. Bamford, X. Fan, S. E. Crowe et al., "Lymphocytes in the human gastric mucosa during *Helicobacter pylori* have a T helper cell 1 phenotype," *Gastroenterology*, vol. 114, no. 3, pp. 482–492, 1998.



Hindawi

Submit your manuscripts at
www.hindawi.com

